

Maternal Postpartum Ovarian Vein Thrombosis Complicating an Intrauterine Death with Hydrops Foetalis Followed by a Successful Pregnancy: a Case Report

V LEE MBBS, MRCOG, FHKAM (O&G)

WL LAU MBBS, MRCOG, FHKAM (O&G)

Department of Obstetrics and Gynaecology

PP IU MBBS, FRCR, FHKAM (Radiology)

Department of Radiology

WC LEUNG MBBS, FRCOG, FHKAM (O&G), Cert RCOG (Maternal and Fetal Med)

R CHIN MBBS, FRCOG, FHKAM (O&G)

Department of Obstetrics and Gynaecology

Kwong Wah Hospital, Hong Kong

Postpartum ovarian vein thrombosis is a rare but serious postpartum complication. The diagnosis is usually made by laparotomy or laparoscopy. With an advance in diagnostic radiology, postpartum ovarian vein thrombosis could be diagnosed by ultrasound and / or computed tomographic scan provided we have considered this diagnosis in postpartum women with fever and localising abdominal pain not responding to antibiotics therapy. The mainstay of treatment is anticoagulation. Here we report a case of postpartum ovarian vein thrombosis complicating an intrauterine death with hydrops foetalis, diagnosed by laparotomy and successfully managed with anticoagulation. Postpartum thromboprophylaxis was given in her subsequent pregnancy.

Hong Kong J Gynaecol Obstet Midwifery 2008; 8:54-7

Keywords: Anti-bacterial agents; Anticoagulants; Tomography, X-ray computed; Venous thrombosis

Introduction

The first case of postpartum ovarian vein thrombosis (POVT) was described by Austin in 1956¹. It is a rare but serious postpartum complication with an incidence of 0.05 to 0.18%^{2,3}. In most cases, the right ovarian vein is involved. The classic triad of clinical presentation includes fever, lower abdominal pain, and a palpable pelvic mass. Differential diagnoses are endometritis, acute appendicitis, adnexal torsion, and pyelonephritis. In the largest series of 11 cases, POVT followed uncomplicated vaginal deliveries in 10 patients, and forceps delivery in one patient⁴. The usual presentation is between 3 and 17 days after delivery. The common presenting symptoms include abdominal, flank, back pain, fever with chills (101-104.6°F), and vomiting, occasionally. Common physical findings include abdominal and adnexal tenderness. The sensitivity and specificity for diagnosis of POVT by computed tomographic (CT) scan is 100% and 99%, by magnetic

resonance imaging 92% and 100%, by ultrasound 50% and 99%, respectively⁵. The mainstay of treatment is anticoagulation such as subcutaneous low-molecular-weight heparin (LMWH⁶) which can subsequently be switched to oral warfarin with international normalised ratio (INR) aimed at 2 to 2.5 times.

Case Report

A 36-year-old Filipino woman had intrauterine death at gestational age 25⁺⁶ week in her first pregnancy. This was a non-consanguineous marriage. She enjoyed good past health. There was no family history of hydrops foetalis or thromboembolism. She attended our Prenatal Diagnosis Clinic in 2004 for advanced maternal age at 18⁺¹ week. The foetal parameters corresponded to

*Correspondence to: Dr WL Lau, Department of Obstetrics and Gynaecology, Kwong Wah Hospital, 25, Waterloo Road, Kowloon, Hong Kong
Email: lauwl@hotmail.com*

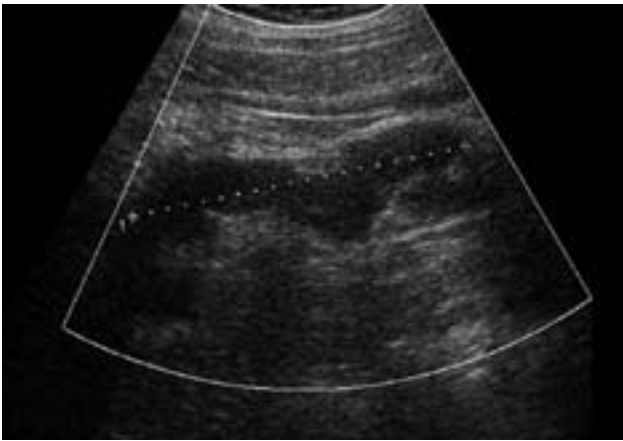


Figure 1. Preoperative ultrasound showing the tubular structure (day 12 post-delivery)

the date except abdominal circumference of 19.6 cm (corresponding to 24+ weeks) which was bigger than date become of generalised foetal skin oedema and marked ascites. Cardiomegaly with CT ratio of 0.70 was noted. Doppler studies of the umbilical artery, middle cerebral artery, and ductus venosus were normal. Investigation results revealed normal mean corpuscular volume (MCV), blood group O+ve, rapid plasma reagin test (RPR) for syphilis non-reactive, positive Rubella immunoglobulin G, TORCH titre negative, normal renal and liver function tests. Amniocentesis revealed normal karyotype of 46XY. Diagnosis of idiopathic hydrops foetalis with poor prognosis was explained to the couple. She was then admitted for brownish spotting at 25⁺³ week with no foetal movement for 5 days. Diagnosis of intrauterine death was confirmed with ultrasound. A 1.7-kg macerated, grossly normal and oedematous male foetus was delivered after induction of labour. Postmortem examination revealed macerated foetus with oedema of soft tissue as well as fluid collection in pericardial, pleural, and abdominal cavities.

The puerperium was complicated by fever (38.2°C) on day 2. She complained of left loin and back pain with right loin tenderness elicited. Intravenous antibiotics were given. Bedside ultrasound for kidneys and pelvis did not show any abnormality. White blood cell count was 11.9×10^9 /L and mid-stream urine showed no growth. In view of the persistent swinging fever, ultrasound was repeated on day 12 showed a tubular collection extending from below the lower pole of right kidney to right iliac fossa with the suspicion of an appendicular abscess (Figure 1). Computed

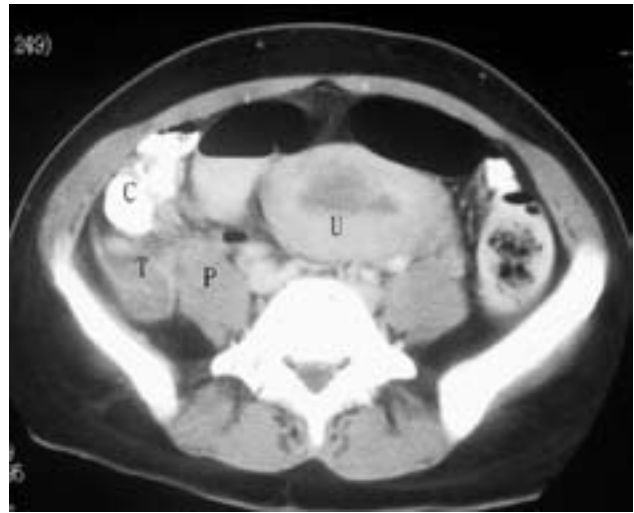

Figure 2. Contrast computed tomographic scan at the level of pelvic brim showing a tubular structure (T), which simulated appendix with lucent centre and enhancing wall, corresponding to the thrombosed right ovarian vein at laparotomy. Caecum (C), right psoas muscle (P), uterus (U)

tomographic scanning of the abdomen and pelvis with contrast was also performed showing the same elongated soft tissue density extending from behind the lower pole of right kidney to right iliac fossa (Figure 2). In view of the possibility of an appendicular abscess with persistent fever, laparotomy was performed. The appendix was normal looking and appendicectomy was performed. A 2-cm diameter tubular mass was found at the origin of the right infundibulopelvic ligament. It was non-pulsatile and extended to the retroperitoneum. Ovarian vein thrombosis was diagnosed which could explain the clinical, ultrasound, and CT findings. Fraxiparine, LMWH, 0.4 ml subcutaneously every 12 hours, was started on day 1 after operation and switched to oral warfarin when the surgical wound haemostasis was ascertained. Retrospective review of the CT films agreed with the surgical diagnosis. Ultrasound on day 18 showed the same tortuous tubular structure extending from lower pole of right kidney to right ovary (2 cm in diameter, 10 cm long). Warfarin was continued for 6 months. Follow-up CT scan performed 4 months afterwards revealed disappearance of the tubular mass. Thrombophilia screening including anti-nuclear antibodies, anti-cardiolipin antibodies, lupus anticoagulant as well as protein C, protein S, and anti-thrombin III were all negative.

One year later, the woman was pregnant again. The option of antepartum thromboprophylaxis was

considered and discussed with the haematologists. No specific guideline was available for this rare condition and it was still controversial whether antepartum thromboprophylaxis was indicated. As the patient was also reluctant for LMWH treatment in the antenatal period, it was not given. On the other hand, postpartum thromboprophylaxis was recommended. The antenatal course was uneventful. Serial ultrasound examinations were performed at first and second trimester revealing normal foetal parameters and the absence of adnexal mass. She had induction of labour at 40⁺² week for large-for-gestational age foetus. A 4180-g baby girl was delivered by emergency lower segment caesarean section for cephalopelvic disproportion. Enoxaparine, LMWH, 40 mg daily subcutaneously was started on day 2 post-delivery and was subsequently switched to oral warfarin. The puerperium was uneventful and warfarin was continued for 6 weeks. There was no adnexal mass on transvaginal ultrasound examination.

Discussion

Postpartum ovarian vein thrombosis can follow a term delivery⁴, a preterm delivery⁷, an abortion⁸, or an ectopic pregnancy⁹. The presenting symptoms and signs such as lower abdominal pain and fever usually do not respond to antibiotics¹⁰. The relationship between hydrops foetalis and POVT has not been reported in the literature except a case report on POVT following a triplet pregnancy complicated by a single intrauterine death¹¹. Our patient developed fever and abdominal pain on day 2 post-delivery of a stillborn. The initial diagnosis was appendicitis. An acute appendicitis-like symptom as initial presentation of POVT has been reported¹². The

differential diagnosis of POVT was not made by our preoperative ultrasound or CT scan. The diagnosis was only made by laparotomy. That was due to the rarity of this condition and thus the low level of clinical suspicion. In various case reports, it has been shown that ultrasound could reveal a tubular anechoic lesion in the right flank area and Doppler studies could be used to show the absence of blood flow, pointing towards the diagnosis of a vascular thrombosis¹³. Computed tomographic scan could demonstrate the thrombotic mass anterior to the psoas muscle, which contained a round low attenuation centre, surrounded by higher attenuation margins of enhancing vessel wall¹³. There are also reports of extension of thrombus into the inferior vena cava, some cases requiring the insertion of filter in the postpartum period¹⁴. It is likely that the diagnosis could be made by ultrasound / CT scan with higher clinical suspicion of this rare condition. Anticoagulation is the mainstay of treatment. The dosage suggested in a case report was enoxaparin, 60 mg subcutaneously every 12 hours⁶, while in our patient, fraxiparine 0.4 ml subcutaneously every 12 hours was used. Our patient continued the anticoagulation by warfarin, with INR between 2 and 2.5, for 6 months after delivery. Recurrent POVT in subsequent pregnancies has not been reported in literature, and the need for anticoagulation prophylaxis is controversial. It remains to be established whether patients who had POVT associated with thrombophilia carry a greater risk of thrombosis in subsequent pregnancies than patients without thrombophilia¹⁴. In our patient, thrombophilia screening was negative, postpartum anticoagulation prophylaxis was given for 6 weeks in her subsequent pregnancy on an empirical basis.

References

1. Austin OG. Massive thrombophlebitis of the ovarian veins; a case report. *Am J Obstet Gynecol* 1956; 72:428-9.
2. Brown TK, Munsick RA. Puerperal ovarian vein thrombophlebitis: a syndrome. *Am J Obstet Gynecol* 1971; 109:263-73.
3. Zuckerman J, Levine D, McNicholas MM, et al. Imaging of pelvic postpartum complications. *AJR Am J Roentgenol* 1997; 168:663-8.
4. Witlin AG, Sibai BM. Postpartum ovarian vein thrombosis after vaginal delivery: a report of 11 cases. *Obstet Gynecol* 1995; 85:775-80.
5. Twickler DM, Setiawan AT, Evans RS, et al. Imaging of puerperal septic thrombophlebitis: prospective comparison of MR imaging, CT, and sonography. *AJR Am J Roentgenol* 1997; 169:1039-43.
6. Beigi RH, Wiensfeld HC. Enoxaparin for postpartum ovarian vein thrombosis. A case report. *J Reprod Med* 2004; 49:55-7.
7. Giraud JR, Poulain P, Renaud-Giono A, et al. Diagnosis

- of post-partum ovarian vein thrombophlebitis by color Doppler ultrasonography: about 10 cases. *Acta Obstet Gynecol Scand* 1997; 76:773-8.
8. Sreenarasimhaiah S, McAlister R. Ovarian vein thrombosis after elective abortion. *Obstet Gynecol* 2000; 96:828-30.
 9. Govaerts I, Braude P, De Paepe J, et al. Postpartum ovarian veins thrombophlebitis. *Eur J Obstet Gynecol Reprod Biol* 1994; 57:56-8.
 10. Smith MD, Felker RE, Emerson DS, et al. Sonographic visualization of ovarian veins during the puerperium: an assessment of efficacy. *Am J Obstet Gynecol* 2002; 186:893-5.
 11. Skinner J, Greene RA, Stuart B. Puerperal ovarian vein thrombosis in a triplet pregnancy complicated by a single intrauterine death. *J Obstet Gynaecol* 1997; 17:585.
 12. Prieto-Nieto MI, Perez-Robledo JP, Rodriguez-Montes KA, et al. Acute appendicitis-like symptoms as initial presentation of ovarian vein thrombosis. *Ann Vasc Surg* 2004; 18:481-3.
 13. Lee EH, Im CY, Kim JW. Ultrasound diagnosis of postpartum ovarian vein thrombosis: case report. *Ultrasound Obstet Gynecol* 2001; 18:384-6.
 14. Dessole S, Capobianco G, Arru A, et al. Postpartum ovarian vein thrombosis: an unpredictable event: two case reports and review of the literature. *Arch Gynecol Obstet* 2003; 267:242-6.